

The effects of topical application of phytonadione, retinol and vitamins C and E on infraorbital dark circles and wrinkles of the lower eyelids

T Mitsuishi,¹ T Shimoda,¹ Y Mitsui,² Y Kuriyama² & S Kawana¹

¹Department of Dermatology, Nippon Medical School, Tokyo, Japan

²Japan Natural Laboratory Co Ltd, Tokyo, Japan

Summary

Background Infraorbital dark circles and wrinkles of the lower eyelids are a cosmetic problem, especially with age.

Aims To determine whether a gel containing 2% phytonadione, 0.1% retinol and 0.1% vitamins C and E is effective in reducing dark under-eye circles and wrinkles of the lower eyelids in healthy Japanese adults.

Patients/Methods Fifty-seven adult Japanese volunteers with dark under-eye circles and wrinkles were enrolled in an open label study. The gel formulation was applied twice daily to the lower eyelid site for 8 weeks. Haemostasis, pigmentation and wrinkles were evaluated by a physician and by the patients themselves, using a digital camera and a visual analogue scale respectively, after 4 and 8 weeks of treatment.

Results Topical application of the gel decreased not only haemostasis but also wrinkles after 8 weeks of treatment. Of 57 patients, 27 (47%) had reductions in haemostasis. Wrinkles were also decreased in some patients. However, pigmentation was not clearly removed by this gel.

Conclusions Topical application of the gel containing 2% phytonadione, 0.1% retinol, 0.1% vitamin C and 0.1% vitamin E was fairly or moderately effective in reducing dark under-eye circles, especially in cases of haemostasis, over a short treatment period in healthy Japanese adults. This treatment also slightly decreased wrinkles.

Keywords: infraorbital dark circles, phytonadione, retinol, vitamin C, vitamin E, wrinkles

Introduction

The aim of this study was to determine whether a gel containing phytonadione, retinol, and vitamins C and E is an effective treatment for infraorbital dark circles (haemostasis and/or pigmentation) and wrinkles of the lower eyelid. In general, the causes of infraorbital dark circles are as follows:

- haemostasis: age and persistent tiredness may result in stasis of the bloodstream in the infraorbital region and increase redness or a blue to black colour;

- pigmentation: age and UVA result in the formation of melanocytes in the area.
- Lichenification with post-inflammatory hyperpigmentation.¹

Initially, topical phytonadione treatment was used in the treatment of traumatic purpura, however, the mode of action was not understood.^{2,3} According to some reports, topical application of phytonadione reduced bruising after laser treatment compared with a placebo.^{4,5} Retinol (vitamin A alcohol) is used in various cosmetic formulae and is able to decrease facial wrinkles.^{2,3} The safety of applying retinol to the face has been established in the cosmetic field.⁴ Vitamin E has also been documented to decrease wrinkles.⁴ In contrast, a study of human skin showed clinical improvement of melasma and senile freckles when utilizing vitamin C (magnesium ascorbyl phosphate).⁵ We attempted to determine the effects of a

Correspondence: Tsuyoshi Mitsuishi, MD, PhD, Department of Dermatology, Nippon Medical School, 1-1-5, Sendagi, Bunkyo-ku, Tokyo 113-8602, Japan, E-mail: tmitsu@nms.ac.jp

Accepted for publication 1 June 2004

gel containing phytonadione, retinol, and vitamins C and E on infraorbital dark circles and wrinkles of the lower eyelids in healthy Japanese adults.

Materials and methods

Fifty-seven Japanese adult volunteers with infraorbital dark circles and/or wrinkles on their eyelids were enrolled in an open label study. The patients were 16 males and 41 females, with a mean age of 34.5 years (range 22–57 years). Patients had moderate to advanced infraorbital dark circles and/or wrinkles of the eyelids, and did not take any medication during the study. Patients with atopic dermatitis were excluded from this study. The topical gel consisted mainly of 2% phytonadione, 0.1% retinol, 0.1% vitamin C (magnesium ascorbyl phosphate) and 0.1% vitamin E (tocophenol) prepared in a water/oil emulsion. The gel was applied topically twice daily to the lower eyelids for 8 weeks. Haemostasis, pigmentation and wrinkles were evaluated by a physician and by the patients themselves using a digital camera (Canon EOS D60, 629×10^6 pixels) and visual analogue scale (VAS: 100 mm line with 0 = no haemostasis, pigmentation or wrinkles, 100 = worst or no response), respectively, at 4 and at 8 weeks.

Results and discussion

Topical application of the gel not only decreased haemostasis, but also reduced wrinkles after 8 weeks (Figs 1, 2; Table 1). Of the 57 patients in the study, 11 (19%) found the gel to be fairly effective in reducing bruising, 16 (28%) found it to be moderately effective, 14 (25%) slightly

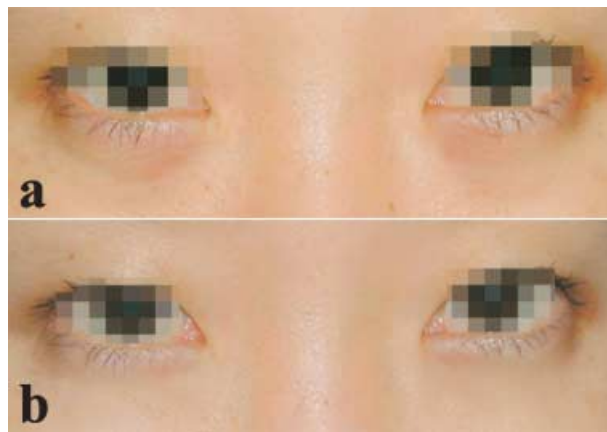


Figure 1 (a, b) Resolution of haemostasis on the bilateral lower eyelid after 8 weeks.

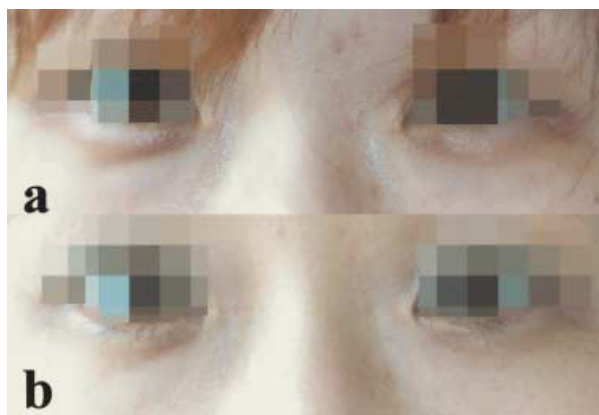

Figure 2 (a, b) After 8 weeks, swelling and infraorbital dark circles decreased in size and colour on the bilateral lower eyelid.

effective and 11 (19%) not effective (Table 2). Five patients developed contact dermatitis although the dose of the vitamin mixture used was low. These results might derive from differences in skin characteristics, such as skin barrier function or the size of melanosomes between whites and Asians. In fact, the skin of the lower eyelid is very thin so that application of various ointments or creams can readily penetrate the epidermis. However, in this study, increased pigmentation due to ageing or other factors was not clearly demonstrated. Although low doses of vitamin C were not effective in reducing infraorbital dark circles caused by dominant pigmentation, some reports have indicated that the application of a lotion containing high doses of vitamins is effective in reducing facial pigmentation.⁶ In this study, many infraorbital dark circles disappeared following application of the gel, which suggests that most dark under-eye circles in young adults result from haemostasis and that the effects depend on the depth of haemostasis in the dermis.

Vitamin K is composed of two naturally occurring forms. One, vitamin K1 (phytonadione) is found in various green plants and the other, vitamin K2, is primarily synthesized by intestinal bacteria.⁷ Although systemic phytonadione is an integral factor in the hepatic biosynthesis of some coagulation factors, topical application of phytonadione is useful in removing haemostasis and clearing purpura, particularly early on.⁴ However, the reason for this discrepancy and the mode of action of the effect on haemostasis and purpura is still not understood. In fact, topical treatment with phytonadione can remove microangiopathy, and vitamin E can improve the cardiovascular system to reduce lipid peroxidation, which results in the reduction or clearing of bruising on the lower eyelid.

Shah *et al.* reported that unknown peripheral effects of topical phytonadione decrease the severity of bruising.⁵ We found the gel to be fairly or moderately effective in 47% patients who had haemostasis of the lower eyelid; this supports other published studies concerning the efficacy of topical phytonadione in the treatment of purpura, bruising and haemostasis.^{2,3,5,7} The mechanism whereby the application of phytonadione is effective at reducing purpura or haemostasis of the lower eyelid, so-called infraorbital dark circles, remains to be resolved.

Conclusion

Topical application of the gel was fairly or moderately effective in reducing infraorbital dark circles, especially in haemostasis, over short treatment periods in healthy Japanese adults. This treatment also slightly decreased wrinkles.

Acknowledgements

We thank Prof Howard Maibach for critical reading of the manuscript.

References

- 1 Mizuno J, Kusumi. In: O Urushibata, Y Miyachi, M Honda, eds. *Cosmetic Dermatology Practice*, 1st edn. Tokyo: Nanzando; 1999: pp. 444–8 [in Japanese].
- 2 Elson ML. Topical phytonadione (vitamin K1) in the treatment of actinic and traumatic purpura. *Cosmet Dermatol* 1995; **8**: 25–7.
- 3 Lou WW, Quintana AT, Geronemus RG, Grossman MC. Effects of topical vitamin K and retinol on laser-induced purpura on nonlesional skin. *Dermatol Surg* 1999; **25**: 942–4.
- 4 Lupo MP. Antioxidants and vitamins in cosmetics. *Clin Dermatol* 2001; **19**: 467–73.
- 5 Shah NS, Lazarus MC, Bugdodel R, Hsia SL, He J, Duncan R, Baumann L. The effects of topical vitamin K on bruising after laser treatment. *J Am Acad Dermatol* 2002; **47**: 241–4.
- 6 Kameyama K, Sakai C, Kondoh S, Yonemoto K, Nishiyama S, Tagawa M, Marata T, Ohnuma T, Quigley J, Dorsky A, Bucks D, Blanock K. Inhibitory effect of magnesium 1-ascorbyl-2-phosphate (VC-PMG) on melanogenesis *in vitro* and *in vivo*. *J Am Acad Dermatol* 1996; **34**: 29–33.
- 7 Thorp JA, Gaston L, Caspers DR, Pal ML. Current concepts and controversies in the use of vitamin K. *Drugs* 1995; **49**: 376–87.

Copyright of Journal of Cosmetic Dermatology is the property of Blackwell Publishing Limited and its content may not be copied or emailed to multiple sites or posted to a listserv without the copyright holder's express written permission. However, users may print, download, or email articles for individual use.