

# MAJOR REVIEW

## Madarosis

J.J. Khong, MBBS (Hons), R.J. Casson, FRANZCO, S.C. Huilgol, FRACD, and D. Selva, FRANZCO

*Oculoplastic and Orbital Unit, Department of Ophthalmology and Visual Science, Royal Adelaide Hospital, University of Adelaide, Adelaide, Australia*

**Abstract.** Madarosis may be a presenting feature of a number of vision and life-threatening conditions, including herpes zoster, leprosy, HIV/AIDS, trachoma, malignant eyelid tumors, discoid lupus, scleroderma, and hypothyroidism. It may occur via two broad pathogenic pathways: scarring and non-scarring, which indicates the potential for lash re-growth. Madarosis may occur as an isolated finding or together with loss of other body and scalp hair. The etiology of madarosis can be further divided into dermatological, infection, endocrine, neoplastic, drug-related, congenital, and trauma. This report includes salient points in the clinical history and examination of patients with madarosis, with an emphasis on excluding or diagnosing visual or life threatening disorders associated with madarosis. (*Surv Ophthalmol* 51:550–560, 2006. © 2006 Elsevier Inc. All rights reserved.)

**Key words.** congenital • dermatological • drug • endocrine • eyelash loss • infection madarosis • milphosis • neoplastic • trauma

### I. Introduction

The term *madarosis* (Greek madao = to fall off) originally described eyelash loss secondary to destruction of the hair follicles,<sup>19</sup> but in contemporary usage, describes the loss of eyelashes from any cause, and it is also used to describe the loss of eyebrow hair.<sup>6,19,28,35,63</sup> Other terms that are used to describe eyelash loss include *milphosis* (a falling out of the eyelashes), *alopecia adnata* (an underdevelopment of the eyelashes), and *hypotrichosis* (a reduction in hair numbers).

In this review, however, the term madarosis will describe eyelash and eyebrow loss due to any cause. Madarosis may be the presenting feature of a number of vision and life-threatening conditions, including herpes zoster,<sup>22</sup> leprosy,<sup>7,15,46,61</sup> HIV/AIDS,<sup>39</sup> trachoma, malignant eyelid tumors,<sup>8,22</sup> discoid lupus,<sup>1,58</sup> scleroderma,<sup>54</sup> and hypothyroidism.<sup>56,66</sup>

This review discusses the pathogenesis, etiology, and differential diagnosis of madarosis and describes the recommended approach to evaluation of these patients in an ophthalmology practice.

### II. Anatomy

Eyelashes are thick, curved hairs at the margin of the lids formed by keratinocytes of the hair bulb. Structurally they are made of hard keratin,<sup>37</sup> and they are arranged in a double or triple row,<sup>6</sup> with a total of 100 to 150 cilia per lid and have an average life of 3–5 months.<sup>6,22</sup> They serve both protective and cosmetic functions.<sup>6,17</sup> The nerve plexus centered on the hair follicles has a very low excitatory threshold, and stimulation leads to a brisk blink reflex. In the hair follicle, sebaceous glands secrete oily sebum that tracks up the lash to lubricate and

protect the eye. Any disease that affects the eyelashes can ultimately affect the health of the lid and the eye.

### III. Pathogenesis

Madarosis may occur via two broad pathogenic pathways: scarring and non-scarring. This classification is useful because it indicates the potential for lash re-growth.<sup>37</sup> In non-scarring processes, the hair follicles are retained and hence the loss is potentially reversible. Non-scarring madarosis may be caused by an inflammatory process or by an alteration in the hair cell cycle kinetics.<sup>3,37,53</sup> The hair follicle is located deep within the subcutaneous tissue; hence, superficial inflammatory diseases such as psoriasis, seborrheic dermatitis, and atopic dermatitis generally have only minor and transient effects on hair growth.<sup>37</sup> In madarosis secondary to scarring, the hair follicles are destroyed, and because hair follicles are formed only as epithelial down-growths between the second and fifth months of fetal life,<sup>53</sup> this form of madarosis is irreversible.

Non-scarring madarosis is caused by a number of pathological mechanisms, but severe inflammation is absent. In alopecia areata, there is an inflammatory lymphocytic process around the lower third of the hair follicle and the hair bulb.<sup>38,42</sup> Occasionally the inflammation is just sufficient to produce a mild shrinking of the hair bulb resulting in a narrowed hair, but usually the lymphocytic inflammation converts an anagen (growing hair) to a telogen (resting hair) in an active patch of alopecia areata.<sup>37,47,49,51</sup> As a result, the hairs are noted to be either in early anagen, which often predominates or in dystrophic telogen structures.<sup>2,47</sup> Immunologic mechanisms are implicated in the pathogenesis of alopecia areata in many studies.<sup>3,37,47,49,55</sup> Approximately 25% of patients with alopecia areata are noted to have a positive family history,<sup>37</sup> and there seems to be an increased incidence of other autoimmune disorders, such as diabetes mellitus, thyroid disease, vitiligo, pernicious anemia, and Addison disease, suggesting an autoimmune etiology.

In seborrheic blepharitis, eyelash loss is related to folliculitis and trauma from lid rubbing due to pruritis.<sup>31,49</sup> Although the specific etiology is unknown, it is associated with excessive secretion of the sebaceous glands and the presence of *Pityrosporum ovale*.<sup>49</sup>

All hair follicles undergo periodic hair cycling moving from growth (anagen) to involution of the follicles by apoptosis (catagen) to resting phase (telogen).<sup>2,27,53</sup> Hormones and their receptors, such as thyroid hormone, glucocorticoids, insulin growth

factor I, and prolactin, modulate postnatal hair cycling.<sup>2</sup> Thyroid hormonal disturbance cause madarosis by affecting the hair cell cycle kinetics.<sup>11,28,43,53</sup> Rook et al demonstrated the effect of hormonal changes on the pattern of hair growth and found that in both hyperthyroidism and hypothyroidism the ratio of telogen to anagen hairs is increased.<sup>53</sup> Similarly, Comaish found that in hypothyroidism, the telogen:anagen hair ratio is increased, and that the hair shaft diameter is decreased.<sup>11</sup> He postulated that hair loss in hypothyroid cases was due to both early arrest of anagen and a failure of initiation of the growing phase.<sup>11</sup> In recent years, thyroid hormone receptors have been localized in the hair follicles indicating that thyroid hormones may affect hair growth and the hair cell cycle directly rather than just through indirect effect on general metabolism.<sup>2,5,24,43</sup> The nuclear receptors vitamin D receptor (VDR) and retinoid receptors (RXR) are also essential for hair cycling.<sup>2</sup> Patients with vitamin D-dependent rickets type IIA (VDDR IIA) with mutation in the VDR gene on chromosome 12 appear normal at birth but lose their hair at approximately 1 to 2 months of age.<sup>69</sup> The mechanism of alopecia in defective VDR gene is related to the failure of induction of anagen in the first postnatal hair cycle.<sup>2</sup> Mutation of hairless gene (Hr) on chromosome 8 also leads to similar clinical picture as VDDR IIA.<sup>69</sup> The Hr gene product has recently been shown to be a nuclear co-repressor that interacts with nuclear receptors in the hair follicle in vitro.<sup>2</sup>

Contrary to superficial inflammatory diseases, severe destructive processes, such as malignant tumors or discoid lupus erythematosus, lead to permanent eyelash loss.<sup>37</sup> Scarring or cicatricial madarosis can result from any deep inflammation leading to fibrosis of the subcutaneous lid tissue. Although dermatoses cause mostly non-scarring madarosis, in severe cases, permanent lash loss can still occur;<sup>49</sup> tendency to painful fissuring leads to destruction of cilia and replacement by scar tissue. A number of other dermatological diseases produce deep inflammation, including lupus erythematosus, lupus vulgaris, tertiary syphilis, and folliculitis decalvans,<sup>6,49</sup> leading to cicatricial madarosis. Autoimmune mechanisms are implicated in the pathogenesis of discoid lupus erythematosus.<sup>1</sup> Discoid lupus erythematosus typically demonstrates histology features of hyperkeratosis with perivascular lymphocytic infiltration of the dermoepidermal junction and telangiectasis of the substantia propria.<sup>1</sup> Lepromatous leprosy is known to cause cicatricial madarosis due to a histiocytic dermal infiltrate preventing normal hair growth.<sup>31</sup> Mvogo et al suggested that madarosis due to leprosy could

be due to direct invasion of bacilli which are abundant in the multibacillary form.<sup>46</sup>

### IV. Etiology

Madarosis may occur as an isolated finding or together with loss of other body and scalp hair.<sup>17,22,37</sup> The causes could be divided according to lid scarring and non-scarring processes and also according to a clinical classification. Causes are summarized in Table 1.

#### A. DERMATOLOGICAL DISORDERS

Alopecia areata, non-scarring hair loss in a circumscribed area of the scalp, can include the brows and lashes, as does alopecia totalis, total hair loss of the head, and alopecia universalis, total hair loss of the body (Fig. 1).<sup>37</sup> Similarly, inflammatory dermatoses, such as seborrheic dermatitis, psoriasis, allergic and contact dermatitis, acne rosacea, and follicular mucinosis, cause superficial inflammation and transient madarosis.<sup>37</sup> Seborrheic blepharitis often co-exists with staphylococcus blepharitis.<sup>22</sup> Discoid lupus erythematosus (Fig. 2), scleroderma, lamellar ichthyosis characterized by cicatricial lagophthalmos and ectropion, follicular lichen planus, pseudopa-

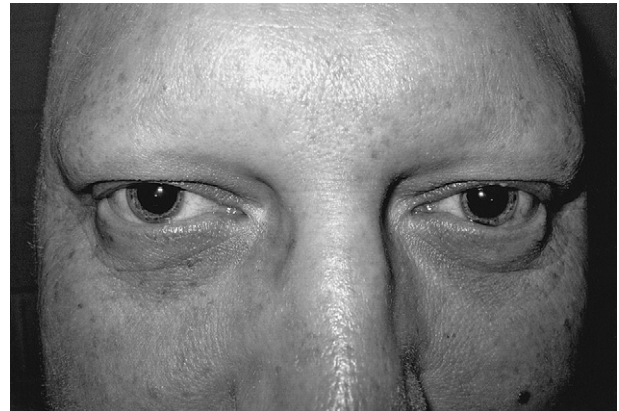

Fig. 1. Alopecia totalis with complete loss of eyebrow and eyelashes.

lade, and erythema ophryogenes lead to scarring madarosis.<sup>1,12,17,22,37,49,54,58</sup> A scleroderma band, known as *coup de sabre*, typically extends from the forehead into the scalp and into the eyebrow and upper lid with focal losses of brows and lashes.<sup>49</sup> Cutaneous amyloidosis has a predilection for eyelids, nasolabial folds, scalp, sides of the neck and intertriginous regions. Alopecia can develop as a result of cutaneous infiltration of the eyebrow, scalp, axillary, and pubic area.<sup>49</sup> Discoid lupus

TABLE 1

*Causes of Madarosis*

Skin disease	Alopecia areata, <sup>3,6,19,28,37,48</sup> psoriasis, <sup>6,29,49</sup> contact and atopic dermatitis, <sup>19,22,49</sup> seborrheic blepharitis, <sup>22,48</sup> seborrheic dermatitis, <sup>6,49</sup> acne rosacea, <sup>49</sup> exfoliative dermatitis, <sup>29,49</sup> follicular mucinosis, <sup>3,37,49</sup> lichen planus, <sup>37</sup> scleroderma, <sup>37,49</sup> epidermolysis bullosa, <sup>6</sup> ichthyosis, <sup>28,29</sup> discoid lupus erythematosus, <sup>1,58</sup> cutaneous sarcoidosis, <sup>30</sup> amyloidosis, <sup>49</sup> dermatophytosis, <sup>28</sup> acrodermatitis, <sup>28</sup> neurodermatitis, <sup>28,29</sup> pseudopelade, <sup>3,18,37</sup> ulerythema ophryogenes, <sup>6,49</sup> Vogt-Koyanagi-Harada syndrome, <sup>49,65</sup> telogen effluvium, <sup>3,37</sup> anagen effluvium, <sup>3,37</sup> mitochondriopathy, <sup>20</sup> Stevens-Johnson Syndrome <sup>60</sup>
Infectious disease	Infective blepharitis (e.g., staphylococcal blepharitis), <sup>6,22,28,49</sup> herpes zoster, <sup>22,49</sup> herpes simplex, <sup>28,49</sup> bacteria folliculitis, vaccinia, <sup>29</sup> furuncles, <sup>29</sup> erysipelas, <sup>29</sup> leprosy, <sup>7,15,46,61</sup> secondary and tertiary syphilis, <sup>3,6,29,37,54</sup> cholera, <sup>28,54</sup> severe tuberculosis, <sup>29,37,54</sup> dermatophyte infection with microsporum, <sup>49</sup> fungal kerion formation with trichophyton, <sup>3,18</sup> demodex folliculorum, <sup>10</sup> paracoccidioidomycosis, <sup>13</sup> lupus vulgaris, <sup>6,49</sup> dissecting cellulitis, folliculitis decalvans, <sup>6,37,49</sup> HIV infection <sup>39</sup>
Endocrine disease	Hyperthyroidism, <sup>2,18,28,29,37</sup> hypothyroidism, <sup>2,3,6,21,56,66</sup> hyperparathyroidism, <sup>2,18</sup> hypoparathyroidism, <sup>18,28</sup> hypopituitarism, <sup>37</sup> pituitary necrosis syndrome <sup>28</sup>
Drugs	Miotics, <sup>28,49</sup> anticoagulants, <sup>28,37</sup> anticholesterol drugs, <sup>28</sup> antithyroid drugs e.g. thiouracil, <sup>28,37</sup> antimetabolites e.g. doxorubicin, cyclophosphamide, methotrexate, colchicine, <sup>3,29,37</sup> boric acid, <sup>28</sup> bromocriptine, <sup>3,28</sup> propranolol, <sup>3,37</sup> valproic acid, <sup>28</sup> arsenic, <sup>28,29</sup> bismuth, <sup>29</sup> thallium, <sup>28,29,37</sup> barbiturates, <sup>29</sup> gold, <sup>29</sup> quinine, <sup>28,29</sup> vitamin A, <sup>28,37</sup> epinephrine, <sup>29</sup> botulinum toxin A <sup>34</sup>
Trauma	Radiation, <sup>68</sup> chemical, electrical and thermal burn, <sup>18,22,37</sup> post eyelid surgery, eyelid tattooing, <sup>63</sup> cryotherapy, <sup>28</sup> lid lacerations, <sup>28</sup> avulsion, <sup>23</sup> cocaine vapor, <sup>62</sup> trichotillomania <sup>3,28,40,59,64</sup>
Neoplasm	Malignant-squamous cell carcinoma, <sup>8,22</sup> basal cell carcinoma, <sup>8,22</sup> sebaceous gland carcinoma, <sup>8,16,22,52</sup> cutaneous T cell lymphoma, <sup>3,22,36</sup> malignant melanoma, <sup>8,22</sup> leukaemia, <sup>18</sup> sclerosing sweat gland carcinoma <sup>32</sup> Benign-wart, <sup>22</sup> molluscum, <sup>8</sup> nevi, <sup>22</sup> seborrheic keratoses, <sup>22</sup> benign adnexal tumors <sup>22</sup>
Congenital	Acanthosis nigricans, <sup>9</sup> anhidrotic ectodermal dysplasia, <sup>6,18</sup> polydysplastic epidermolysis bullosa, <sup>6,18,29</sup> oculomandibular dysostosis, <sup>6,18</sup> oculovertebral dysplasia, <sup>6,18</sup> progeria, <sup>3,6</sup> atrichia congenital, <sup>6,18</sup> lamellar ichthyosis, <sup>12</sup> congenital hair shaft abnormalities e.g. monilethrix <sup>3,6,49</sup> and pili torti, <sup>6,49</sup> cryptophthalmos, <sup>28</sup> Ehlers-Danlos syndrome, <sup>28</sup> lid coloboma, <sup>28,57</sup> Rothmund-Thomson syndrome, <sup>3,49</sup> hereditary hypotrichosis, <sup>49</sup> adrenomyeloneuropathy, <sup>33</sup> erythrokeratoderma variabilis, <sup>42</sup> IFAP syndrome, <sup>14</sup> KID syndrome, <sup>44</sup> atrichia with papular lesions, <sup>69</sup> vitamin D-dependent rickets type IIA <sup>69</sup>

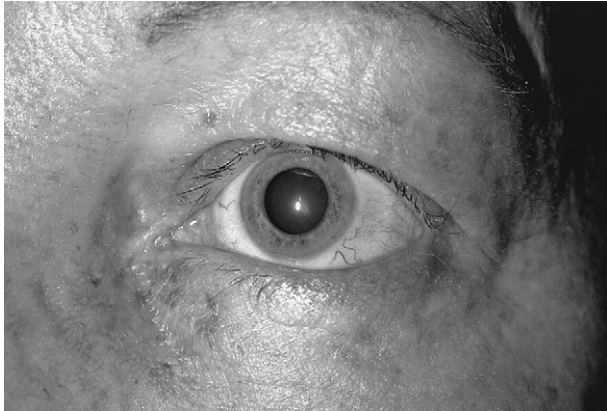


Fig. 2. Madarosis due to lupus erythematosus with erythematous scaling at the margin of lower eyelid. Differential diagnosis includes chronic blepharitis.

erythematosus that involve the lid margin often has a predilection to the lower and outer eyelid margin.<sup>1,58</sup> Acharya et al reported a case series of five patients with discoid lupus erythematosus masquerading as chronic blepharoconjunctivitis all with delayed diagnosis ranging from 4 months to 25 years.<sup>1</sup> Clinical features included meibomian gland dysfunction, blepharitis, chalazia, trichiasis, madarosis, conjunctivitis, and chronic eyelid edema.<sup>1</sup>

Telogen effluvium and anagen effluvium are dermatoses characterized by abnormalities in hair growth cycle. Telogen effluvium is characterized by shedding of large amount of normal hair in the resting state associated with stressors like surgery, parturition, acute febrile illness, severe physical or emotional trauma.<sup>3,37</sup> Anagen effluvium is the loss of growing hair following administration of chemotherapeutic agents that resulted in abrupt thinning and breaking of growing hair shafts.<sup>3</sup> Vogt-Koyanagi-Harada syndrome is a rare cause of madarosis that

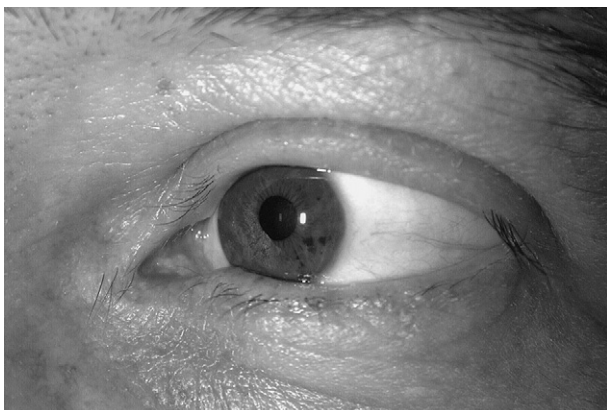


Fig. 3. Patchy loss of eyelashes due to blepharitis showing fine scales at the lid margins.

could be associated with meningoencephalitis, poliosis, vitiligo, uveitis, and hearing impairment.<sup>6,65</sup> Other rare causes of madarosis include cutaneous sarcoidosis presenting as leonine facies due to enlarging non-caseating granulomatous nodules and plaques on the face,<sup>30</sup> mitochondriopathy,<sup>20</sup> sickle cell anaemia,<sup>54</sup> and Stevens-Johnson syndrome.<sup>60</sup>

## B. INFECTION

Infection of the lids by *Staphylococcus* is the most common cause of non-scarring madarosis (Fig. 3).<sup>22</sup> A wide variety of bacteria may be pathogenic, including *Streptococcus*, *Haemophilus*, *Moraxella*, and *Neisseria*.<sup>22</sup> Other non-scarring infective causes include bacterial folliculitis, herpes zoster, herpes simplex, and parasitic infestation.<sup>48,49</sup> Infestation of the eyelashes with *Demodex folliculorum* may be associated with madarosis. It is, however, debatable if this is a direct association or indirectly related to an increase in *Staphylococcus aureus* colonization.<sup>10</sup> Madarosis can also be caused by secondary syphilis and dermatophyte infections with microsporum.<sup>37,49</sup>

Deep cutaneous infections, such as leprosy, may infiltrate the lid margin.<sup>7</sup> In non-institutionalized leprosy patients in the USA, 46% had scarring madarosis, noted more commonly in the lepromatous disease (68%) as compared to the tuberculoid disease (25%), and also more common in patients with longer disease duration.<sup>15,61</sup> In non-institutionalized leprosy patients in India, madarosis was the most common eye lesion (76%) and it was seen in lepromatous and borderline lepromatous leprosy.<sup>61</sup> Approximately 90% of the patients with madarosis had a disease duration longer than 10 years.<sup>15</sup> Paracoccidioidomycosis is a systemic infection that occurs in Latin America. Of 439 patients with acute, subacute, or chronic paracoccidioidomycosis in Brazil, 11 (2.5%) had eyelid involvement.<sup>13</sup> Active lesions ranged from erythematous patches of madarosis to frank destructive ulcers indistinguishable from malignancies.<sup>13</sup> Healed lesions were characterized by a high degree of fibrosis, cicatricial malpositions (entropion or ectropion) and fusion of eyelid tissues to the globe with madarosis a constant finding in the inactive lesions.<sup>13</sup> Other deep infections include syphilis, lupus vulgaris, dissecting cellulitis, folliculitis decalvans, necrotic herpes zoster, herpes simplex and fungal kerion formation with *Trichophyton* species.<sup>3,6,17,22,28,37,49,54</sup> Severe chronic blepharitis may also cause cicatricial blepharitis.<sup>49,50</sup>

## C. ENDOCRINE

Endocrinopathies affecting both eyelashes and scalp hair include hyperthyroidism, hypothyroidism,

hyperparathyroidism, hypoparathyroidism, hypopituitarism, and pituitary necrosis syndrome.<sup>2,17,21,28,54,56,66</sup> In hyperthyroidism, hair thins and breaks, causing patchy hair loss. Some degree of diffuse alopecia is present in about 40% of cases.<sup>53</sup> Jordan et al reported a case of unilateral madarosis as the presenting feature of hyperthyroidism.<sup>28</sup> Treatment with propylthiouracil resulted in re-growth of the eyelashes.<sup>28</sup> In hypothyroidism, the hair becomes dull, brittle, and coarse with reduced diameter and areas of hair loss (Fig. 4).<sup>53</sup> Diffuse hair loss was found in 32–49% of patients in different series.<sup>21,56,66</sup> However the response of alopecia in hypothyroidism to thyroxine replacement is variable.<sup>25,26,53,56,67</sup>

#### D. NEOPLASIA

Lid tumors may cause scarring madarosis. These include various benign tumors, such as nevi, seborrheic keratoses, warts, and molluscum contagiosum.<sup>8,22</sup> These benign tumors are characterized by localized, non-invasive growth and usually with no deformation of the lid margin.<sup>22</sup> Malignant tumors that present with madarosis may be associated with posterior lid margin scarring or deformity, leading to loss of the normal lid margin architecture (Fig. 5). These include basal cell carcinoma, squamous cell carcinoma, and sebaceous cell carcinoma. They can present as recurrent chalazia or chronic blepharoconjunctivitis. Mortality of sebaceous cell carcinoma is about 30% and approaches 83% if both eyelids were involved.<sup>16,29,52</sup> The infiltrative and morpheic histological subtypes of basal cell carcinoma, in particular, may involve the lid margin without an obvious mass effect. Cutaneous malignant melanoma, sclerosing sweat duct carcinoma, cutaneous T cell lymphomas, and

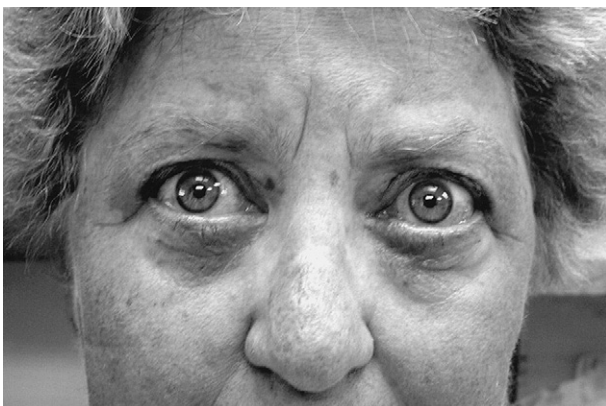


Fig. 4. Madarosis in hypothyroidism with lateral eyebrow loss.

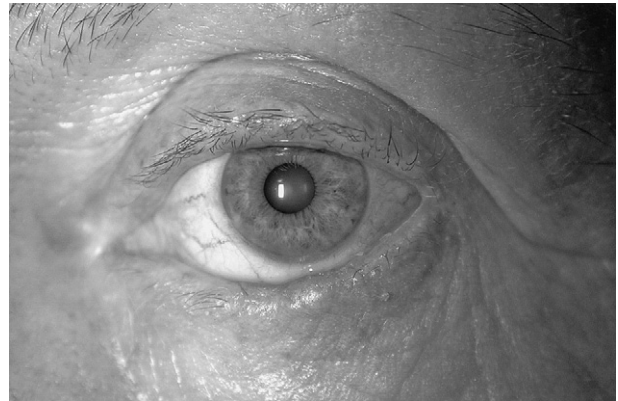


Fig. 5. Nodular basal cell carcinoma characterized by the pearly appearance. Note the focal loss of eyelashes and the irregular lower lid margin in the middle portion.

leukemia could also involve the eyelids and lead to madarosis, but are rare.<sup>17,22,32,36,52</sup>

#### E. DRUGS

A number of drugs have been reported to cause madarosis, including miotics,<sup>28,49</sup> anticoagulants,<sup>28,37</sup> anticholesterol drugs,<sup>28</sup> antithyroid drugs,<sup>28,37</sup> boric acid,<sup>28</sup> bromocriptine,<sup>3,28</sup> propranolol,<sup>3,37</sup> valproic acid,<sup>28</sup> chronic topical epinephrine therapy,<sup>29</sup> and botulinum A toxin injection.<sup>34</sup>

#### F. CONGENITAL DISORDERS

Congenital hair shaft abnormalities, such as monilethrix and pili torti, lead to brittle hairs, and they result in loss of eyelashes and eyebrows.<sup>37,49</sup>

Other congenital causes leading to lash loss and eyebrow loss include ichthyosiform erythroderma,<sup>12</sup> adrenomyeloneuropathy,<sup>33</sup> erythrokeratoderma variabilis,<sup>42</sup> anhidrotic ectodermal dysplasia,<sup>6,18,54</sup> polydysplastic epidermolysis bullosa,<sup>6,18,29</sup> oculomandibular dysostosis,<sup>6,18</sup> oculovertbral dysplasia,<sup>6,18</sup> progeria,<sup>3,6,18</sup> lid coloboma,<sup>57</sup> Ehlers-Danlos syndrome,<sup>28</sup> cryptophthalmos,<sup>28</sup> and hereditary hypotrichosis.<sup>49</sup>

Other rare causes include atrichia with papular lesions (APL) and VDDR IIA, which are two genetically distinct forms of atrichia with similar phenotypic features of congenital or early onset scalp atrichia with loss of eyelashes or eyebrows;<sup>69</sup> syndromic neuroichthyosis, such as ichthyosis follicularis, atrichia, and photophobia (IFAP) syndrome;<sup>14</sup> keratitis-ichthyosis-deafness (KID) syndrome due to congenital ectodermal dysplasia;<sup>44</sup> Rothmund-Thomson syndrome, which is an autosomal recessive dermatosis characterized by poikiloderma and absence of eyelashes and brows in 50%

of cases;<sup>3,49</sup> and familial acanthosis nigricans due to ectodermal defect.<sup>9,54</sup>

### G. TRAUMA

Alopecia artefacta is the result of purposeful epilation of the brow to sculpt its contours. Radiation exposure may result in non-scarring madarosis (Fig. 6).<sup>54,68</sup> Severe trauma, such as caustic chemical burns, deep second and third degree burns, radiation dermatitis, eyelid pigment implantation procedure,<sup>63</sup> thermal and electrical burns, and avulsion, leads to scarring and permanent loss of eyelashes.<sup>23</sup>

Trichotillomania is an impulsive control disorder defined as irresistible urge to pluck own hair to achieve a sense of relief.<sup>40</sup> The behavior is often concealed and hence the diagnosis is a difficult one to make. In trichotillomania, hair loss is usually reversible. It is differentiated from alopecia by the absence of inflammation, atrophy, or scarring, and pathologically demonstrates an atrophic follicle.<sup>40,41,59</sup> Formation of heavily pigmented keratinous material and softening of the hair shaft are also characteristic features of trichotillomania.<sup>40,41,59</sup> In a histopathologic study of 66 patients with trichotillomania, Muller noted that the most specific histological findings were increased numbers of catagen hairs, pigment casts, and traumatized hair bulbs.<sup>45</sup>

## V. Evaluation of the Patient Presenting with Madarosis

### A. HISTORY

A careful history and examination will reveal most of the causes of madarosis. In addition to an

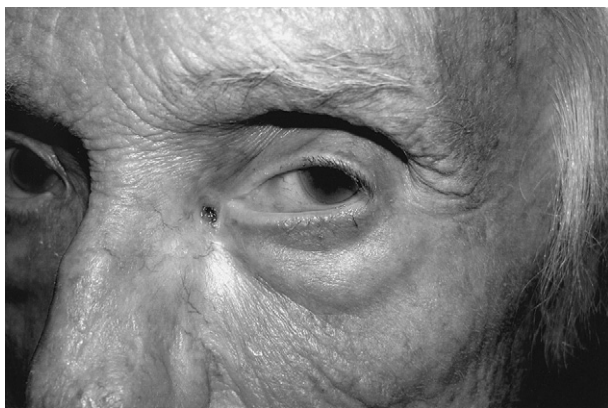


Fig. 6. Medial loss of eyelashes both upper and lower lid due to radiotherapy for medial canthal squamous cell carcinoma.

ophthalmic history, it is important to obtain a general medical and dermatological history.

It is important to determine whether the lash loss is an isolated event or is occurring in conjunction with other hair loss. Madarosis associated with other hair loss from the eyebrows or scalp suggests dermatological, endocrinological, drug-induced, systemic diseases, or congenital causes. Conversely, isolated madarosis is more likely to result from localized eyelid disease.

Blepharitis is probably the most common isolated condition that is associated with madarosis, which may be the presenting feature; hence an inquiry into the typical symptoms of blepharitis should be included in the history-taking.

The presence of chronic chalazion suggests the possibility of sebaceous gland carcinoma. History-taking should also include inquiry into past eyelid or ocular infection—in particular, previous herpetic infection. Any past history of eyelid surgery for malignancy, radiotherapy to the periocular region, and cryotherapy, hyfrecation, or laser tricholysis for trichiasis should also be elicited.

A thorough medical history detailing skin conditions, including alopecia areata, discoid lupus erythematosus, dermatitis, and psoriasis, should be taken. In addition, an endocrine history, including the presence of diseases such as hyper- and hypothyroidism, hypopituitarism, and hyper- and hypoparathyroidism should be taken. For instance, patients may also present with weight gain, tiredness, and other constitutional symptoms of reduced metabolism in hypothyroidism.

Patients with alopecia areata often present with sudden onset of patchy hair loss on the scalp and beard area in addition to eyelash and eyebrow loss in an otherwise healthy individual.<sup>3,37</sup> Contact dermatitis is characterized by a history of unilateral or bilateral pruritis, erythema, vesiculation, or exudation. Skin around the eyes tends to develop massive edema. Chronic contact dermatitis leads to thickening, scaling, and crusting of the eyelid. It might be caused by cosmetics applied to the eyelids or inadvertently touching the eyelids with contaminated fingers. Possible causative agents include nail polish, mascara (due to the emulsifiers and solvents), atropine, chloramphenicol, penicillin, sulfathiazole, neomycin, procaine, and antazoline.<sup>49</sup> Seborrheic dermatitis presents as a chronic and pruritic inflammatory condition of the skin with predilection for the scalp, forehead, eyebrows, eyelids, nasolabial folds, lips, and the postauricular, presternal, and intertriginous areas.<sup>6,49</sup> Patients may complain of irritation, burning, and itching of the lid with tendency of painful fissuring in seborrheic blepharitis. In addition, the patient might notice

greasy, moist or dry scales and erythematous, yellowish-pink patches without distinct margins.<sup>49</sup> Patients with atopic dermatitis might disclose a history of other atopic conditions like asthma and allergic rhinitis. Trigger factors might be identified, including certain foods, wool clothing, or stress. Cutaneous features include intense pruritis, erythema, fissuring, thickening, lichenification, and fine scales.<sup>49</sup> Atopic dermatitis can be associated with other ocular diseases, such as keratoconjunctivitis, vernal conjunctivitis, keratoconus, atopic cataract, and retinal detachment.<sup>49</sup> Atopic conjunctivitis can be accompanied by herpes simplex keratitis and secondary staphylococcal blepharoconjunctivitis.<sup>49</sup> Moderate-to-severe dermatitis can also cause madarosis. Typically there is history of scalp seborrheic dermatitis, or atopic or contact dermatitis in association with marginal blepharitis. If marginal blepharitis is not present, then dermatitis is unlikely to be the cause of madarosis.<sup>48</sup> Psoriasis presents as a chronic, recurrent condition. The face is usually spared but 10% of patients develop ocular symptoms and signs.<sup>49</sup> The clinical features of ocular psoriasis include pruritis, epiphora, and photophobia. Patients notice fine, scaly, erythematous patches on the eyelids associated with edema and thickening of skin. In severe cases of ocular psoriasis, madarosis can develop. Lupus erythematosus, a condition commoner in women can present as discoid lupus erythematosus<sup>1,58</sup> where only the skin is involved or systemic lupus erythematosus, which involves not only the skin, but also the renal, cardiopulmonary, gastrointestinal, and rheumatologic systems due to the vasculitic process.

Family history may reveal the presence of inherited dermatological conditions, and a careful psychosocial history may indicate a diagnosis of trichotillomania; however, patients will characteristically conceal this behavior.<sup>40,59,64</sup>

## B. EXAMINATION

Routine ocular examination aims to exclude visual threatening ocular pathology associated with some causes of madarosis. The examination includes close inspection of the eyelids and periocular skin. Stubs of residual lash among normal lashes located predominantly on the upper eyelid favors a diagnosis of trichotillomania.<sup>40,59,64</sup> Lupus erythematosus and chronic blepharitis should be considered in the presence of telangiectasia of the lid margin.<sup>49</sup> Absence of any eyelid inflammation suggests a hormonal imbalance or trichotillomania.<sup>3,37,50</sup> Vesiculation and ulceration are characteristics of herpes zoster and herpes simplex infection. Distortion or destruction of the palpebral surface

indicates a malignant and focally invasive lesion. Erythema, scaly and crusty rash with or without exudation or vesiculation on the lid indicates dermatitis.<sup>22,49</sup> It is sometimes associated with marginal blepharitis, which presents as swollen erythematous and granular lid margins with fine adherent scales between the eyelashes.

Psoriasis, lupus erythematosus, and acne rosacea may be difficult to distinguish from dermatitis. Lupus erythematosus rash has a violaceous hue and well-defined margins compared to dermatitis, which has a less distinct margin and a lesser degree of alopecia.<sup>49</sup> Dermatitis is also typically not associated with the atrophic or dilated follicles typical of lupus.<sup>22,49</sup> Acne rosacea is a chronic acneiform eruption commonly associated with chronic blepharitis and keratitis and erythema, papules, pustules, and telangiectasia on the face and nose. Rosacea is differentiated from lupus by the absence of atrophic follicles, coarser telangiectasia, the presence of pustules, and rhinophyma.<sup>49</sup> Lupus erythematosus is distinguished by the typical appearance and distribution of the rash. Discoid lupus erythematosus has the characteristic discoid erythematous to violaceous scaling and slightly elevated skin patches. Systemic lupus erythematosus produces chronic inflammation of the skin with a predilection for the sun-exposed areas such as the face (forming a butterfly pattern), forehead, ears, scalp, and dorsum of the hands that heals with scarring, telangiectasia, and depigmentation.<sup>49</sup> The scarring process may lead to permanent loss of the eyelashes and distortion of the lid margins. Keratitis, conjunctivitis, and scleritis may also be observed.<sup>49</sup> Psoriasis on the eyelid may extend to the conjunctiva to form discrete yellowish-red conjunctival plaques. It may also present as slightly raised papules with silvery scales that coalesce into plaques. Other indicators of psoriasis include grid-like pitting of the nails, distribution on the extensor surfaces, and a Koebner reaction (exacerbation at sites of trauma).<sup>22,49</sup>

Madarosis may be the presenting feature or part of the constellation of signs and symptoms of hyperthyroidism. Hair loss may be diffuse, with thinning, breaking and shortening of hair, or it may be patchy at the upper and lower lids and occiput.<sup>26,28</sup> In hypothyroidism, hair becomes dull, coarse, and brittle with decreased diameter of the shaft.<sup>11,26</sup> Loss of lateral third of eyebrows and loss of eyelashes are commonly observed in association with diffuse scalp alopecia.<sup>11,26</sup> The other characteristic feature is generalized myxedema that occurs most prominently around the eyelid. The skin appears puffy and feels boggy.<sup>49</sup>

General hair loss should also be assessed. Circumscribed patchy hair loss of scalp or brows suggests

alopecia areata. Hair loss that progresses to all body areas is suggestive of alopecia universalis.<sup>3,19,37</sup>

In regions where leprosy is prevalent then the presence of madarosis should suggest this condition and the examination should be directed to detect other clinical features, including leonine facies, corneal hypesthesia, prominent corneal nerves, and granulomatous uveitis with iris pearls.<sup>15</sup> Common diagnoses of madarosis are presented in Table 2 and its clinical evaluation is summarized in Table 3.

### C. INVESTIGATIONS

Certain investigations may be required to confirm the underlying diagnoses, including calcium and parathyroid hormone (PTH) levels for hyperparathyroidism and hypoparathyroidism; thyroid stimulating hormone (TSH), follicular stimulating hormone (FSH), and luteinizing hormone (LH) levels to check the pituitary function; and double-stranded DNA antibody, anti-nuclear antibody (ANA) in combination with anti-Ro and anti-La, for the diagnosis of lupus erythematosus.

Residual eyelashes from the lid or the residual hairs from scalp could be plucked and examined. Trichotillomania is characterized by traumatized hair bulb in catagen or anagen state.<sup>45,59</sup> Microscopic examination of shed eyelash or hair showing anagen roots is also suggestive of trichotillomania because anagen hair never shed spontaneously.<sup>49</sup> This is in comparison to alopecia areata where the hair root would be atrophied.<sup>50</sup> The “exclamation point” hair obtained from a fresh patch of alopecia areata has a clubbed root, proximal depigmenta-

tion, and thicker distal end. Its presence is pathognomonic of alopecia areata.<sup>37,48</sup> Presence of both damaged and normal hair follicles in the same area, plugging of the empty follicles with heavily pigmented soft keratinous material, and softening of the hair shaft are characteristics of trichotillomania.<sup>41</sup> In alopecia areata, skin biopsy shows chronic lymphocytic infiltration around the hair follicles.<sup>3,49</sup> Full-thickness lid biopsy should also be performed for chronic chalazion and progressive non-resolving blepharitis to exclude the diagnosis of sebaceous carcinoma.<sup>22</sup>

If a non-ophthalmic cause is suspected, then madarosis is probably best managed in association with a dermatologist or physician.

### VI. Treatment for Madarosis

The potential for lash re-growth depends on the underlying etiology. Lash and brow re-growth is expected after correcting reversible causes for non-scarring madarosis such as inflammatory dermatoses and endocrinopathies. Reconstruction of the eyebrow or eyelashes and camouflaging cosmesis could be considered for scarring madarosis where hair follicles are destroyed in deep dermal infections, deep inflammatory dermatoses, severe trauma or malignancy, and for congenital causes where hair follicles may be absent.

Intralesional injections of corticosteroid suspensions are the treatment choice for localized patches of conspicuous eyebrow loss in alopecia areata if there is no spontaneous re-growth.<sup>3,49</sup> High-strength

TABLE 2

*Common Differential Diagnoses for Madarosis with Associative Clinical Features*

Isolated madarosis +/- ocular involvement	Infection (e.g., infective blepharitis, necrotic herpes, leprosy) Focal tumor (e.g., basal cell carcinoma, squamous cell carcinoma, sebaceous gland carcinoma) Trauma (e.g., lid surgery, tricholysis, radiation, cryotherapy, burns, trichotillomania) Dermatoses (e.g., seborrheic blepharitis, alopecia areata) Topical medications (e.g., atropine, epinephrine) Endocrinopathies (e.g., hypothyroidism, hyperthyroidism)
Madarosis with periocular and facial skin rash	Dermatoses (e.g., seborrheic dermatitis, atopic dermatitis, contact dermatitis, rosacea, discoid or systemic lupus erythematosus, psoriasis) Infection (e.g., herpes zoster, dermatophytes infection)
Madarosis with alopecia	Alopecia areata, alopecia totalis, alopecia universalis Telogen effluvium, anagen effluvium Endocrinopathies (e.g., hypothyroidism, hyperthyroidism) Dermatoses (e.g., seborrheic dermatitis, systemic lupus erythematosus) Congenital disorders (e.g., monilethrix, pili torti, atrichia) Systemic medications (e.g., anticoagulant, antimetabolites, bromocriptine, thallium) Trichotillomania
Madarosis with multi-organ involvement	Sarcoidosis Amyloidosis Scleroderma Systemic lupus erythematosus Malignancy (e.g., cutaneous T cell lymphoma) Infections (e.g., tertiary syphilis, paracoccidioidomycosis)



TABLE 3  
*Clinical Evaluation of Madarosis*

History	Examination	Investigation
Isolated madarosis or in combination with other hair loss	Inspection of lids, lashes and periocular skin	As directed by clinical findings:
Associated ocular, dermatological and constitutional features	Distribution of hair loss	Blood tests—full blood examination, erythrocytes sedimentation rate, PTH, TSH, FSH, LH, double stranded DNA, ANA, ENA (e.g., anti-Ro, anti-La)
Medical co-morbidities	Skin condition of the face, scalp and body	Microscopic examination of lashes
Dermatological co-morbidities	Full ocular examination	Skin or lesion biopsy
Ophthalmic history	Full medical examination	
Past history of lid surgery, trauma and radiation		
Medication list		
Family history		

topical steroid creams, topical minoxidil, either alone or in combination, may also be considered as alternative therapies.<sup>3</sup> For more widespread alopecia, induction of allergic and contact dermatitis to topical agents, such as diphencyprone, squaric acid dibutyl ester, and dinitrochlorobenzene, yield occasional successes but they include the risk of adverse effects; therefore, they are not recommended as routine treatment.<sup>3,4,49</sup> In a series of patients with alopecia totalis and universalis who were treated with topical diphencyprone and topical tretinoin gel to their scalp, Ashworth et al reported that one of the three patients who achieved therapeutic response with diphencyprone on the scalp also re-grew eyebrows and eyelashes without direct treatment.<sup>4</sup> Hence, there might be a role for topical sensitizer in eyebrows and lashes re-growth. Rigorous testing of corneal toxicity is needed to address safety issue of these topical sensitizing agents before applying them close to the ocular surface.

Latanoprost, an analog of prostaglandin F<sub>2α</sub>, is used clinically in the treatment of glaucoma. It induces growth of eyelashes and the adjacent adnexal hair and vellus hair of the skin. Increase in the length, numbers, and rows; increase in the thickness of lashes; and conversion of vellus to terminal hairs around the canthal areas and the skin were noted in association with increased pigmentation.<sup>27</sup> Although the underlying mechanism of latanoprost-induced hypertrichosis is not well understood, stimulated transition of hair follicles from telogen to anagen phase, follicular hypertrophy in early anagen, delayed cessation of anagen, influence on rapid remodeling of extracellular matrix surrounding the advancing hair follicles, and trophic stimulation have been postulated.<sup>27</sup> Latanoprost has been reported to reverse drug-induced alopecia of

the eyelashes in one patient, suggesting that it is a potential therapy for lash re-growth.<sup>38</sup>

Cosmetic eyelash camouflage could be achieved with the use of mascara in partial eyelash loss and eyeliner in near total or complete absence of lashes. Artificial eyelashes can also be employed either with a complete set of lashes, demi-lashes, or lash singlets, which are affixed to existing lashes or eyelid margin with methacrylate-based adhesive. However cutaneous irritation from the artificial lash fibers, glue, and solvent and allergic contact dermatitis may develop.<sup>17</sup> Permanent pigment tattooing or blepharopigmentation has also been employed for cosmetic improvement.<sup>17</sup> Successful autologous hair transplantations were observed in patients with inactive leprosy where the recipient site may have an influence on the growth pattern of the transplanted hair.<sup>35</sup>

## VII. Conclusion

Although blepharitis is the most common cause of madarosis, madarosis may infrequently be the presenting feature of several vision and life-threatening conditions. A broad range of dermatological conditions can be associated with madarosis and it may be the presenting feature of thyroid dysfunction. The pathogenesis and causes of madarosis can be grouped into those conditions that cause scarring and those that do not with implications for lash re-growth. The causes of madarosis can also be grouped into clinical categories for ease of formulating differential diagnoses. Clinical examination of the patient with madarosis includes both a thorough ophthalmic and dermatological examination, and attempts to exclude serious etiology. When the cause is obscure suspect trichotillomania.

Although the diagnosis is usually made clinically, certain investigations including hormone levels, examination of the hair root, skin biopsy, and biopsy of any associated tumor may be needed. A suspected non-ophthalmic cause is best managed in association with a dermatologist or physician.

### VIII. Method of Literature Search

The literature search was conducted with MEDLINE and Pubmed using the keywords *madarosis* and/or *eyelash loss* for articles from 1966 to December 2005 using reference manager program Endnote, Windows version 7, Thomson ISI. Only English articles were used as references. Other languages have not been included. Additional relevant articles and book chapters of latest edition were obtained and reviewed from the reference lists of all searched publications.

### References

- Acharya N, Pineda R, Uy HS, et al: Discoid lupus erythematosus masquerading as chronic blepharoconjunctivitis. *Ophthalmology* 112:e19-23, 2005
- Alonso LC, Rosenfield RL: Molecular genetic and endocrine mechanisms of hair growth. *Horm Res* 60:1-13, 2003
- Arnold HL, Odom RB, James WD: Diseases of the skin appendages, in Odom RB, James WD, Berger TG (eds): *Andrews' Diseases of the Skin: Clinical Dermatology*. Sydney, WB Saunders, ed 9 2000, pp 943-90
- Ashworth J, Tuyp E, Mackie RM: Allergic and irritant contact dermatitis compared in the treatment of alopecia totalis and universalis. A comparison of the value of topical diphenylprone and tretinoin gel. *Br J Dermatol* 120:397-401, 1989
- Billoni N, Buan B, Gautier B, et al: Thyroid hormone receptor beta1 is expressed in the human hair follicle. *Br J Dermatol* 142:645-52, 2000
- Burton JL, Harrad RA: The skin and the eyes, in Champion RH, Burton JL, Burns DA, et al (eds): *Textbook of Dermatology*. Oxford, Blackwell Science, ed 6 1998, pp 2975-3012
- Cakiner T, Karaçorlu MA: Ophthalmic findings of newly diagnosed leprosy patients in Istanbul Leprosy Hospital, Turkey. *Acta Ophthalmol Scand* 76:100-2, 1998
- Carter SR: Eyelid disorders: diagnosis and management. *Am Fam Physician* 57:2695-702, 1998
- Chuang SD, Jee SH, Chiu HC, et al: Familial acanthosis nigricans with madarosis. *Br J Dermatol* 133:104-8, 1995
- Clifford CW, Fulk GW: Association of diabetes, lash loss, and *Staphylococcus aureus* with infestation of eyelids by *Demodex folliculorum* (Acari: Demodicidae). *J Med Entomol* 27:467-70, 1990
- Comaish JS: The thyroid and hair growth. *Semin Dermatol* 4:4-8, 1985
- Cruz AA, Menezes FA, Chaves R, et al: Eyelid abnormalities in lamellar ichthyoses. *Ophthalmology* 107:1895-8, 2000
- Cruz AA, Zenha F, Silva JT, et al: Eyelid involvement in paracoccidioidomycosis. *Ophthalmol Plast Reconstr Surg* 20:212-6, 2004
- Cursiefen C, Schlötzer-Schrehardt U, Holbach LM, et al: Ocular findings in ichthyosis follicularis, atrichia, and photophobia syndrome. *Arch Ophthalmol* 117:681-4, 1999
- Dana MR, Hochman MA, Viana MA, et al: Ocular manifestations of leprosy in a noninstitutionalized community in the United States. *Arch Ophthalmol* 112:626-9, 1994
- Doxanas MT, Green WR: Sebaceous gland carcinoma. Review of 40 cases. *Arch Ophthalmol* 102:245-9, 1984
- Draelos ZK: Eyelash cosmetics, in Draelos ZK (ed): *Cosmetics in Dermatology*. New York, Churchill Livingstone, ed 1 1990, pp 49-56
- Draelos ZK, Yeatts RP: Eyebrow loss, eyelash loss, and dermatochalasis. *Dermatol Clin* 10:793-8, 1992
- Duke-Elder S, MacFaul P: The ocular adnexa, part I: diseases of the eyelashes in: Duke-Elder S (ed): *System of Ophthalmology*, Vol. 13. St Louis, CV Mosby, 1974, ed, pp 373-90
- Finsterer J, Brunner S: Madarosis from mitochondriopathy. *Acta Ophthalmol Scand* 83:628-30, 2005
- Freedberg IM: Thyroidism. Review of body system. I: skin, in Werner SC, Ingber SH (eds): *The Thyroid*. New York, Harper & Row, ed 3 1971, pp 722-5
- Giovinazzo VJ, Rodríguez-Sains RS: Ophthalmologic oncology: alopecia of the eyelashes. *J Dermatol Surg Oncol* 10:182-5, 1984
- Goldberg SH, Bullock JD, Connelly PJ: Eyelid avulsion: a clinical and experimental study. *Ophthalmol Plast Reconstr Surg* 8:256-61, 1992
- Holt PJ, Lazarus J, Marks R: The epidermis in thyroid disease. *Br J Dermatol* 95:513-8, 1976
- Jackson D, Church RE, Ebling FJ: Hair diameter in female baldness. *Br J Dermatol* 87:361-7, 1972
- James MB, James APR: Prevalence of thyroid abnormality associated with hair loss, in Orfanos CE, Montagna W, Stüttgen G (eds): *Hair Research: Status and Future Aspects*. Berlin, Springer-Verlag, 1981, pp 358-62
- Johnstone MA, Albert DM: Prostaglandin-induced hair growth. *Surv Ophthalmol* 47(Suppl 1):S185-202, 2002
- Jordan DR, Ahuja N, Khouri L: Eyelash loss associated with hyperthyroidism. *Ophthalmol Plast Reconstr Surg* 18:219-22, 2002
- Kass MA, Stamper RL, Becker B: Madarosis in chronic epinephrine therapy. *Arch Ophthalmol* 88:429-31, 1972
- Kendrick CG, Brown RA, Reina R, et al: Cutaneous sarcoidosis presenting as leonine facies. *Cutis* 73:57-62, 2004
- Kingery FA: Eyebrows, plus or minus. *JAMA* 195:571, 1966
- Kodama T, Tane N, Ohira A, et al: Sclerosing sweat duct carcinoma of the eyelid. *Jpn J Ophthalmol* 48:7-11, 2004
- König A, Happle R, Tchitcherina E, et al: An X-linked gene involved in androgenetic alopecia: a lesson to be learned from adrenoleukodystrophy. *Dermatology* 200:213-8, 2000
- Kowing D: Madarosis and facial alopecia presumed secondary to botulinum toxin injections. *Optom Vis Sci* 82:579-82, 2005
- Lee SH, Kim DW, Jun JB, et al: The changes in hair growth pattern after autologous hair transplantation. *Dermatol Surg* 25:605-9, 1999
- Leib ML, Lester H, Braunstein RE, et al: Ocular findings in cutaneous T-cell lymphoma. *Ann Ophthalmol* 23:182-6, 1991
- Maguire HC, Hanno R: Diseases of the hair, in Moschella SL, Hurley HJ (eds): *Dermatology*. Philadelphia, WB Saunders, ed 2 1985, pp 1369-86
- Mansberger SL, Cioffi GA: Eyelash formation secondary to latanoprost treatment in a patient with alopecia. *Arch Ophthalmol* 118:718-9, 2000
- Mansour AM: Adnexal findings in AIDS. *Ophthalmol Plast Reconstr Surg* 9:273-9, 1993
- Mawn LA, Jordan DR: Trichotillomania. *Ophthalmology* 104:2175-8, 1997
- Mehregan AH: Trichotillomania. A clinicopathologic study. *Arch Dermatol* 102:129-33, 1970
- Merchant A, Zhao TZ, Foster CS: Chronic keratoconjunctivitis associated with congenital dyskeratosis and erythrokeratoderma variabilis. Two rare genodermatoses. *Ophthalmology* 105:1286-91, 1998
- Messenger AG: Thyroid hormone and hair growth. *Br J Dermatol* 142:633-4, 2000
- Messmer EM, Kenyon KR, Rittinger O, et al: Ocular manifestations of keratitis-ichthyosis-deafness (KID) syndrome. *Ophthalmology* 112:e1-6, 2005

45. Muller SA: Trichotillomania: a histopathologic study in sixty-six patients. *J Am Acad Dermatol* 23:56–62, 1990
46. Mvogo CE, Bella-Hiag AL, Ellong A, et al: Ocular complications of leprosy in Cameroon. *Acta Ophthalmol Scand* 79: 31–3, 2001
47. Norris D: Alopecia areata: current state of knowledge. *J Am Acad Dermatol* 51:S16–7, 2004
48. Orentreich DS, Orentreich N: Patchy eyelash loss. *JAMA* 252:684, 1984
49. Orentreich DS, Orentreich N: Dermatology of the eyelids, in Smith BC, Della Rocca RC, Nesi F (eds): *Ophthalmic Plastic and Reconstructive Surgery*. St. Louis, CV Mosby, 1987, pp 855–906
50. Orentreich N: Etiology of loss of eyelashes in a child. *JAMA* 207:961, 1969
51. Paus R, Ito N, Takigawa M, et al: The hair follicle and immune privilege. *J Invest Dermatol Symp Proc* 8:188–94, 2003
52. Piest KL: Malignant lesions of the eyelids. *J Dermatol Surg Oncol* 18:1056–9, 1992
53. Rook A: Endocrine influences on hair growth. *Br Med J* 1: 609–14, 1965
54. Roy FH (ed): *Ocular Syndromes and Systemic Diseases*. Orlando, Grune & Stratton Inc, 1985, p 349
55. Safai B, Orentreich N, Good RA: Immunological abnormalities in patients with alopecia areata (AA). *Clin Res* 27:244A, 1979
56. Saito R, Hori Y, Kuribayashi T: Alopecia in hypothyroidism, in Kobori T, Montagna W (eds): *Biology and Disease of Hair*. Baltimore, MD, University Park Press, 1976, pp 279–85
57. Scassellati-Sforzolini G, Scassellati-Sforzolini B: Unilateral giant coloboma of the upper eyelid associated with other congenital anomalies (33 years follow-up of surgical repair). *Eur J Ophthalmol* 13:714–7, 2003
58. Selva D, Chen CS, James CL, et al: Discoid lupus erythematosus presenting as madarosis. *Am J Ophthalmol* 136:545–6, 2003
59. Smith JR: Trichotillomania: ophthalmic presentation. *Aust NZ J Ophthalmol* 23:59–61, 1995
60. Sood GC, Sofat BK, Mehrotra SK, et al: Entropion and madarosis in erythema multiforme. *Indian J Dermatol* 18: 21–2, 1973
61. Soshamma G, Suryawanshi N: Eye lesions in leprosy. *Lepr Rev* 60:33–8, 1989
62. Tames SM, Goldenring JM, et al: Madarosis from cocaine use. *New Engl J Med* 314:1324, 1986
63. Tse DT, Folberg R, Moore K: Clinicopathologic correlate of a fresh eyelid pigment implantation. *Arch Ophthalmol* 103: 1515–7, 1985
64. Ugurlu S, Bartley GB, Otley CC, et al: Factitious disease of periocular and facial skin. *Am J Ophthalmol* 127:196–201, 1999
65. Walsh FB, Hoyt WF: *Clinical Neuro-ophthalmology*. ed 3. Baltimore, Williams & Wilkins Co, ed 3 1969. pp 1380–5
66. Watanakunakorn C, Hodges RE, Evans TC: Myxedema: A study of 400 cases. *Arch Intern Med* 116:183–90, 1965
67. Zaun H: Hormone-induced disorders of hair growth, in Orfanos CE, Montagna W, Stuttgen G (eds): *Hair Research: Status and Future Aspects*. Berlin, Springer-Verlag, 1981, pp 283–6
68. Zehetmayer M, Kitz K, Menapace R, et al: Local tumor control and morbidity after one to three fractions of stereotactic external beam irradiation for uveal melanoma. *Radiother Oncol* 55:135–44, 2000
69. Zlotogorski A, Hochberg Z, Mirmirani P, et al: Clinical and pathologic correlations in genetically distinct forms of atrichia. *Arch Dermatol* 139:1591–6, 2003

---

The authors reported no proprietary or commercial interest in any product mentioned or concept discussed in this article.

Reprint address: Dr Robert Casson, Department of Ophthalmology and Visual Science, Royal Adelaide Hospital, North Terrace, Adelaide, South Australia 5000, Australia.

## Outline

- I. Introduction
- II. Anatomy
- III. Pathogenesis
- IV. Etiology
  - A. Dermatological disorders
  - B. Infection
  - C. Endocrine
  - D. Neoplasia
  - E. Drugs
  - F. Congenital disorders
  - G. Trauma
- V. Evaluation of the patient presenting with madarosis
  - A. History
  - B. Examination
  - C. Investigations
- VI. Treatment for madarosis
- VII. Conclusion
- VIII. Method of literature research